





**Thotta N. Ganesh, B.V.Sc, M.V.Sc,  
Ph.D, F.A.S.I.F (U.K), F.I.S.V.S (India)**  
*Department of Clinical Studies, Faculty of  
Veterinary Medicine, University Malaysia Kelantan*  
E: [thotta.ng@umk.edu.my](mailto:thotta.ng@umk.edu.my)

## LAPAROSCOPIC SURGERIES IN CATS AND DOGS

**Introduction:** Laparoscopic procedures are gaining wider application in veterinary medicine. The advantages of laparoscopic surgeries are: improved visualization, low invasiveness with decreased patient morbidity, small percentage of complications, less pain, shortened hospitalization period, faster recovery, low mortality and higher level of satisfaction with the owners. Laparoscopic surgery, the Minimally Invasive Surgery (MIS) is indicated for diagnostic, therapeutic, advanced therapeutic and prophylactic procedures.

**Equipment:** Most telescopes used in cats and dogs are 5mm dmm (0 and 30 degree angle). Larger dmm (10mm) scopes with or without instrument channel are used at times. The instruments used are Veress needle, trocar/cannula assembly, forceps, haemostats, biopsy forceps, scissors, aspiration needle, needle holders etc. Equipment include light source, camera with control unit, insufflator, cautery, suction unit etc.



*Laparoscopic armamentarium*

**Exploratory laparoscopy:** Exploratory laparoscopy is performed when the findings can prevent unnecessary celiotomy or change the treatment course to result in an improved postoperative outcome for the animal. The benefit of staging laparoscopy is the excellent visualisation of vascular changes in tissue. This benefit, along with the ability to easily obtain material for investigation, and the opportunity to observe for post biopsy haemorrhage or leakage, makes laparoscopy an attractive surgical option for animals with suspected cancer.

**Liver biopsy:** The advantages are biopsy from the lesion, better tissue samples, and multiple biopsies from different sites / lobes, examination of other organs and structures and shorter procedure. Biopsy is obtained by "double spoon" type forceps. Haemorrhage less than 1 to 5ml which is magnified gets arrested spontaneously.

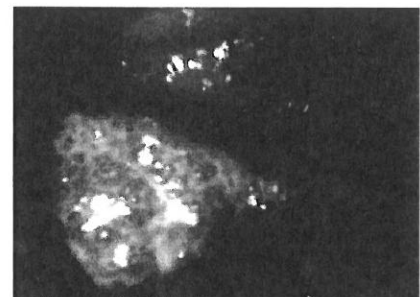
**Pancreatic biopsy:** More commonly done in cats. Performed by double puncture laparoscopy and using "double spoon" type forceps. Biopsy obtained from the edge and both sides are examined to avoid the large vein which runs under.

**Kidney biopsy:** It is generally performed along with hepatic and pancreatic biopsies using a double or single puncture laparoscopy and another small incision for penetration of 14-gauge core biopsy needle.

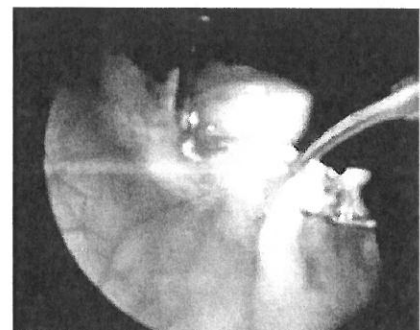
**Biopsy of small intestine:** Double puncture laparoscopy is performed. Babcock forceps is used to gently grasp and pull jejunum with cannula from the abdomen by enlarging the skin incision. Stay sutures are placed in the intestine to perform routine incisional biopsy.

**Retrieval of gastric foreign bodies:** If the foreign body cannot be retrieved by endoscopic approach, a laparoscopic approach may be used. Laparoscopic retrieval should be limited to those cases when the foreign body is small enough to warrant a less invasive approach and when there is not a significant opportunity for spillage of gastric contents during the procedure. Similarly, intestinal foreign bodies can be retrieved.

**Laparoscopic ovariectomy:** Two-portal laparoscopic ovariectomy provides a viable alternative to conventional ovariohysterectomy. Performing either ovariectomies laparoscopically or lap-assisted ovariohysterectomy in bitches and queens reduces the incision size, tissue trauma, and overall level of pain experienced by the patient compared with performing an open ovariectomy or open ovariohysterectomy.



*Hepatocellular adenoma in a dog*



*Oophorectomy – Bitch*

**Laparoscopic cryptorchidectomy:** Retained testis is exteriorized and ligatures performed externally with two (2) portal procedure. Comparing to intra-abdominal removal of testicle, this technique permits reduced operative time, good exposure, laxity of structures and simplifies ligation without the need for specialized devices.

**Prophylactic laparoscopic gastropexy:** A 5mm cannula is placed just caudal to the umbilicus and the second 10mm cannula just right of midline, about 2-4cm behind the last rib (incision parallel to rib). Stomach wall at antrum is pulled through incision (while enlarging) along with Babcock forceps and cannula and stay sutures placed to fix stomach to body wall to perform muscular flap gastropexy. The stomach is re-examined laparoscopically before closure.

**Feeding tube placement:** Although not commonly performed, lap assisted jejunostomy feeding tube placement is a clinically relevant, palliative laparoscopic procedure to provide nutritional support. Potential complications are the same as for open surgery.

**Lap-assisted cystoscopy and calculi retrieval:** After laparoscopic examination, the caudal instrument portal site is enlarged to permit securing the bladder to the abdominal wall and to perform a mini cystotomy for placing the cystoscope. Calculi are removed by using either wire-basket catheters through the operating channel or a variety of the grasping devices passed parallel to the scope. Small calculi can be flushed and aspirated. Before closure, the urethra should be examined.

**Advanced laparoscopic procedures:** Lap-assisted cholecystostomy tube placement, laparoscopic cholecystectomy, and adrenalectomy are technically demanding and should be performed by surgeons with experience of laparoscopic procedures and with experience of performing those procedures in an "open" fashion.

**Complications:** Potential postoperative complications include infection, dehiscence, and herniation at the portal sites. Care must be taken to ensure that the same standards of care expected for "open" procedures are upheld for laparoscopic interventions.

**Challenges:** The learning curve is high and hence, it is mandate to take basic and advanced courses. Further, it is advised to practice sufficiently on endotainers before assisting laparoscopic surgeries and then in real-patients can be done without deviating the concepts. To begin with diagnostic and expand to therapeutic techniques. Surgeon should remember that safety is paramount, and a liberal policy of conversion to an open approach should not be viewed as failure but as evidence of good surgical judgement.

**Summary:** When applied by a surgeon with experience, laparoscopy with minimal invasiveness is a simple, safe and efficient technique to perform diagnostic and surgical operations in cats and dogs. Due to the benefits of laparoscopy, more and more practiced by veterinary surgeons and also opted by owners of the animals. Images and movies are excellent aids for teaching, client education and monitoring of disease.